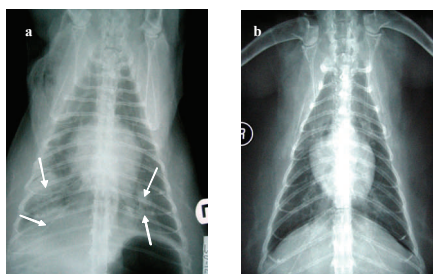


What is Feline Hypertrophic Cardiomyopathy (HCM)?

Feline Hypertrophic Cardiomyopathy (HCM) is the most common heart disease in cats. It is characterised by an abnormally thickened (hypertrophic) myocardium, the muscle that forms the heart wall. Because of its increased thickness, the myocardium becomes stiffer and does not distend enough to allow complete, so a lower blood volume will be pumped into circulation after each heart beat. Eventually, the upper heart chambers (atria) dilate in response to the increased pressure in the lower chambers (ventricles). Initially, the affected cat does not present any noticeable symptoms (compensatory phase). However, with time, the pressure will also increase in the left atrium and, subsequently, in the vessels that carry blood from the lungs to the left atrium. These vessels become engorged with blood and, eventually, fluid will leak from the vessels into the lungs (pulmonary oedema) or chest cavity (pleural effusion). When fluid starts building up in the lungs or chest cavity, the cat starts breathing with difficulty and at a faster rate (usually more than 40-50 breaths per minute). This symptomatic phase of the disease is called “congestive heart failure” or simply CHF. Less commonly, when the pressure increases also in the right atrium, the fluid tends to accumulate also in the abdomen (ascites).

How is HCM treated?

Many cats remain symptom-free for a long time. However, at present, there are no drugs that can prevent the progression of the disease into its symptomatic phase. Once symptoms present, diuretics (water pills) help reduce the amount of fluid in the lungs and chest cavities. In some occasions, fluid in the chest cavity needs to be manually removed with a syringe and needle (thoracocentesis). Diuretics are often used in combination with other drugs depending on the clinical presentation and individual preference of clini-



a) Chest radiographs from a cat with HCM showing enlarged heart and patchy areas in the lungs (arrows) consistent with pulmonary oedema. b) resolution of pulmonary oedema after administration of diuretics

Which cat is affected by HCM?

HCM is an inheritable condition in Maine coon, Ragdolls and British shorthair cats. However, any cat can potentially develop the disease, so an inheritable mechanism may also be present in other breeds, including domestic shorthair cats. The mean age of cats diagnosed with HCM is 6 years, but it may range from 6 months to 16 years. Since the disease tends to be asymptomatic for many months, or even years, HCM is usually diagnosed when it is in an advanced stage and the cat has become symptomatic.

How is HCM diagnosed?

A thorough physical exam coupled with a complete history may lead the clinician to suspect HCM. Often cats

affected by HCM present with a heart murmur, even during their asymptomatic phase. When the disease is advanced, the cat shows the typical symptoms of CHF, which include lethargy, loss of appetite, weight loss, reduced willingness to play or groom, and fast and difficult breathing.



At present, the most suitable test to confirm the presence of feline HCM is echocardiography (ultrasound scanning of the heart). The ultrasound images will show a thicker than normal heart wall and often other related changes, such as bigger atrium, as explained above. However, echocardiography alone is not sufficient to demonstrate the presence of CHF and radiographs will be required to determine the presence of fluid in the lungs (pulmonary oedema), or chest cavity (pleural effusion).

cians. It is not easy to pill a cat! Therefore, treatment is always discussed with the cat owner and adjusted to guarantee the best compliance and minimise stress for the patient.

What is the prognosis of HCM?

The median survival time of cats with HCM is approximately 500 days, although this really depends on the time of diagnosis, development of CHF, concomitant diseases, and individual response to treatment.

